

# 症例4 口腔領域

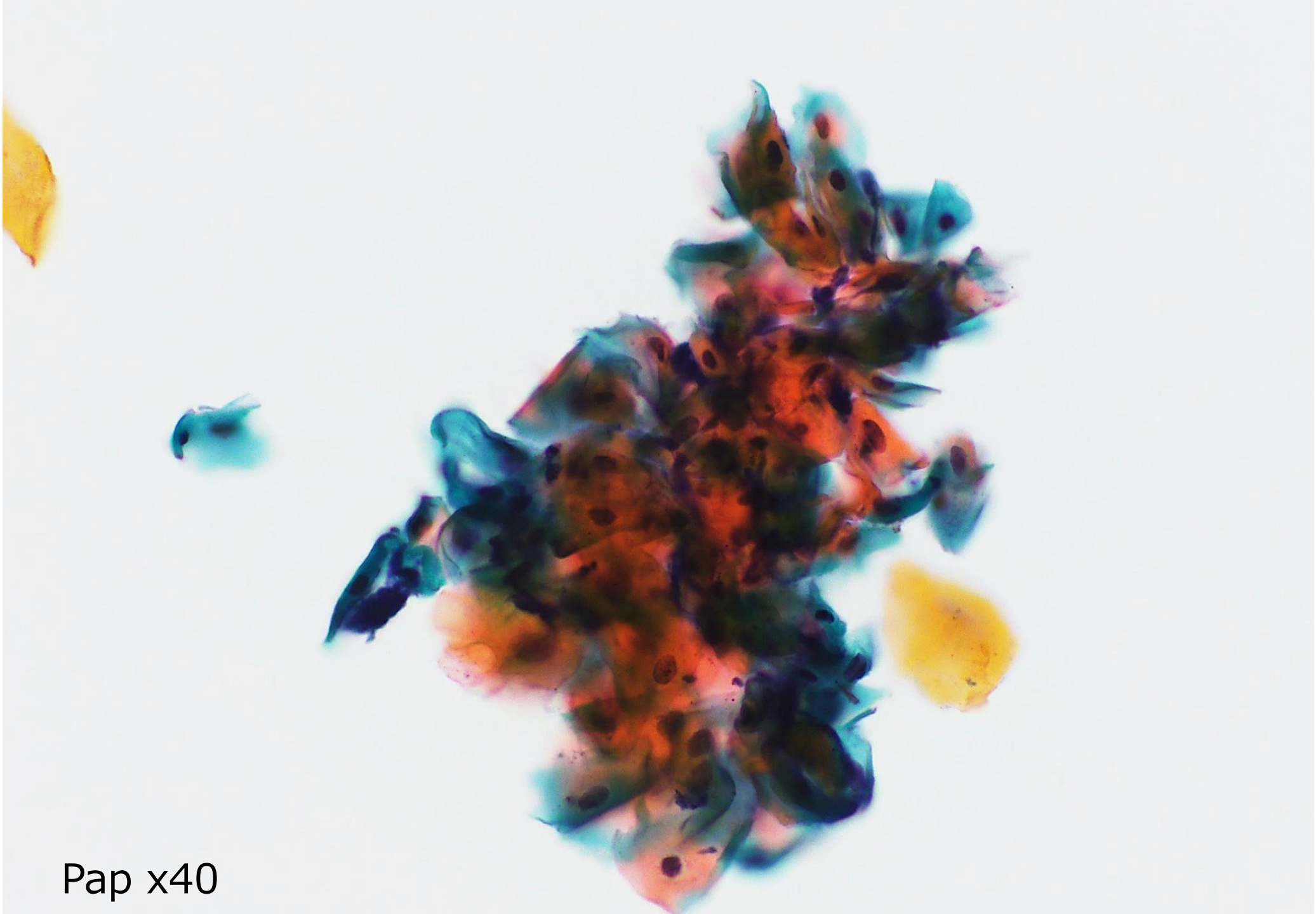
症例：60歳代 男性

臨床所見：口蓋隆起・粘膜に白色病変


検体：口蓋擦過

採取器具：オーセレックスブラシ

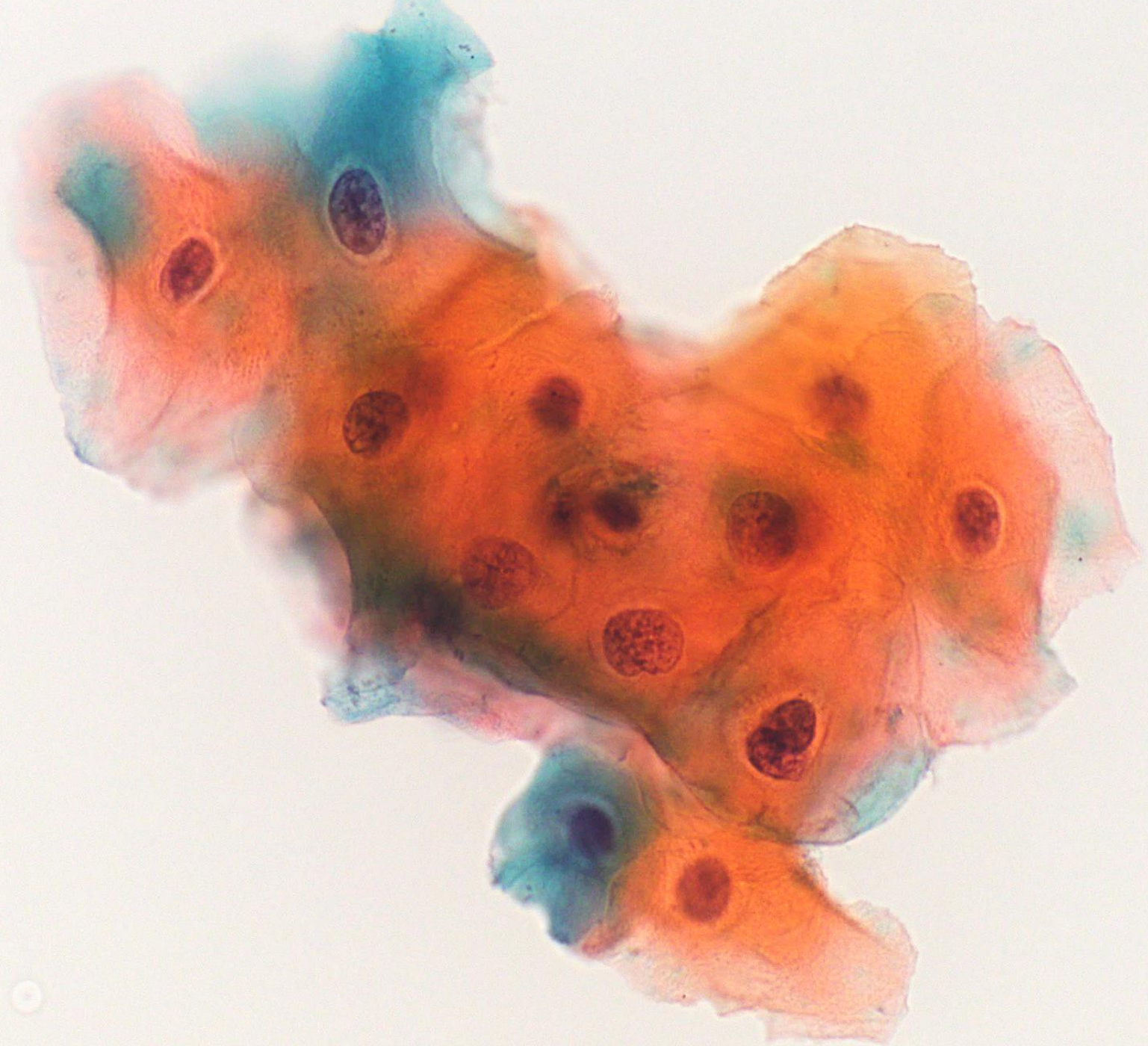
標本：BDサイトリッチ<sup>TM</sup>法



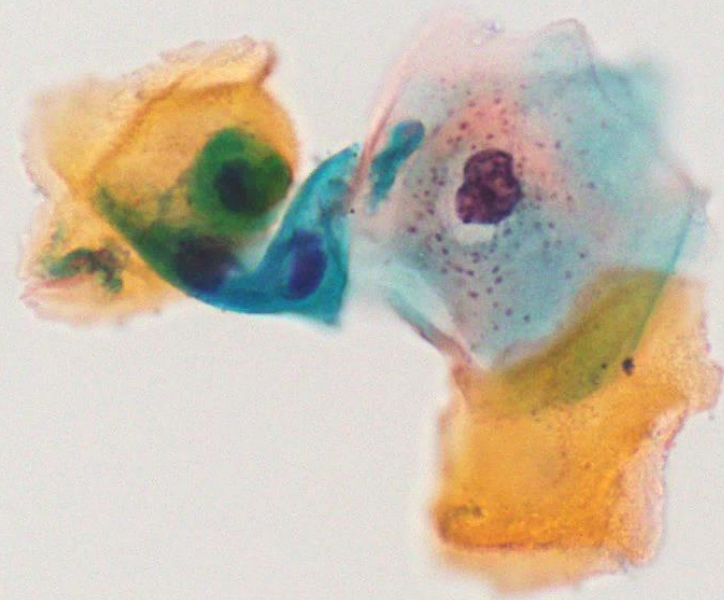
Pap x40




Pap x60



Pap x60



Pap x60



Pap x60

# 【選擇肢】

- ①NILM/過角化症
- ②NILM/尋常性天疱瘡
- ③LSIL/輕度上皮內腫瘍性病變
- ④HSIL/高度上皮內腫瘍性病變
- ⑤SCC/扁平上皮癌